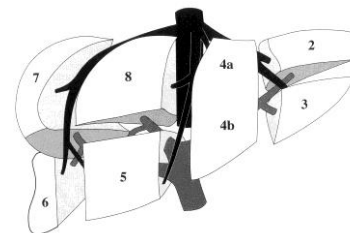


PAEDIATRICS UPPER ABDOMINAL ULTRASOUND

Name:

Sonographer:

Relevant clinical history:



Region

NAD

Comments:

Liver

Size: Normal / Abnormal Texture: Normal / Coarse

Surface: Smooth / Nodular Para-umbilical vein patent: Yes / No

Pancreas

Visualisation: Head Neck Body Tail

Gallbladder

Calculi: Yes / No Tender: Yes / No

Wall Thickness: mm (Normal $\leq 3\text{mm}^1$)



Common Duct

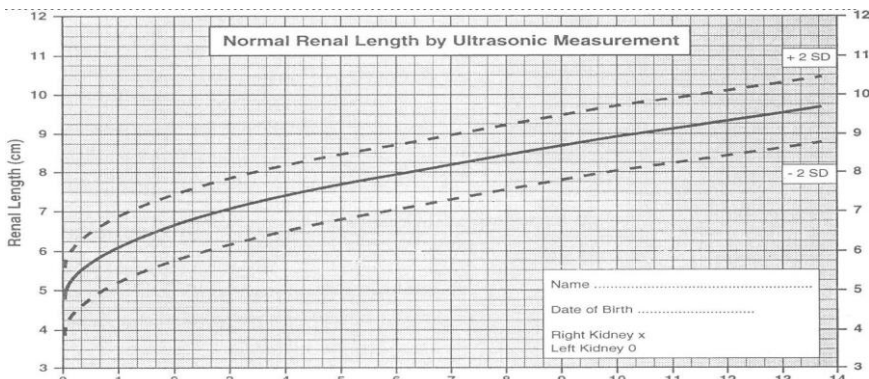
.....mm (Normal $\leq 6\text{mm}^1$ Post cholecystectomy $\leq 10\text{mm}$)

Rt Kidney

.....cm

Lt Kidney

.....cm



Spleen

.....cm (Normal $\leq 12\text{cm}^6$)

Aorta

.....cm A-P (Normal $\leq 2.4\text{cm}$ if patient $\leq 60\text{years}^3$)

IVC

Ascites

Yes / No

Comments:

.....

