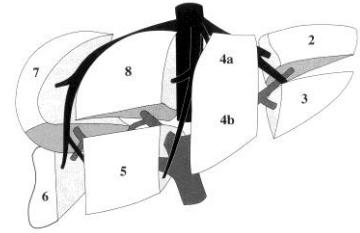


# UPPER ABDOMINAL ULTRASOUND

Name: .....

Sonographer: .....

Relevant clinical history: .....



**Region**

**NAD**

**Comments:**

Liver

Size: Normal / Abnormal    Texture: Normal / Coarse  
 Surface: Smooth / Nodular    Para-umbilical vein patent: Yes / No

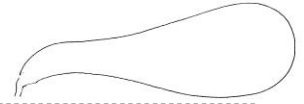Pancreas

Visualisation: Head  Neck  Body  Tail

Gallbladder

Calculi: Yes / No    Tender: Yes / No

Wall Thickness: .....mm (Normal  $\leq 3\text{mm}^1$ )



Common Duct


.....mm (Normal  $\leq 6\text{mm}^1$  Post cholecystectomy  $\leq 10\text{mm}$ )

Rt Kidney

.....cm.....

Lt Kidney

.....cm.....



Spleen

.....cm (Normal  $\leq 12\text{cm}^6$ ).....

Aorta

.....cm A-P (Normal  $\leq 2.4\text{cm}$  if patient  $\leq 60\text{years}^3$ )

IVC

Ascites

Yes / No

Comments: .....